

## Gist in Rif Masquerading As Appendicular Mass

Dr.P.Nancharaiah, Ms<sup>1</sup>, Dr.M.C.Venkateswarlu, Ms<sup>2</sup>, Dr.M.Aishwarya, PG

<sup>1</sup>Professor of Surgery

<sup>2</sup>Assistant Professor, Department Of General Surgery, Siddhartha Medical College/  
Government General Hospital, Vijayawada, AP.

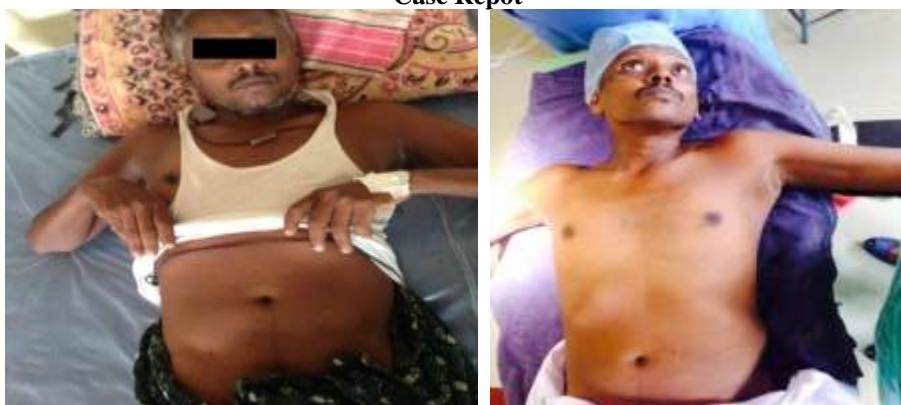**Abstract:** Gastrointestinal stromal tumors (GISTs) are most common(80%) mesenchymal neoplasms of GIT arise from interstitial cell of Cajal. Most common site –stomach (60%) and Jejunum, ileum (30%) and duodenum 5% and in colorectum 4%. GIST is about 0.1–3% of all GI tumors. Clinical presentation of GIST is asymptomatic (mostly) and abdominal pain, bleeding, mechanical obstruction. we report a case of small intestinal (jejunal) GIST in 45 years male, its diagnosis,, Differential diagnosis for Mass in RIF and treatment options.

**Keywords:** GIST, Mass in RIF, Appendicular mass, Resection, Anastomosis.

### I. Introduction

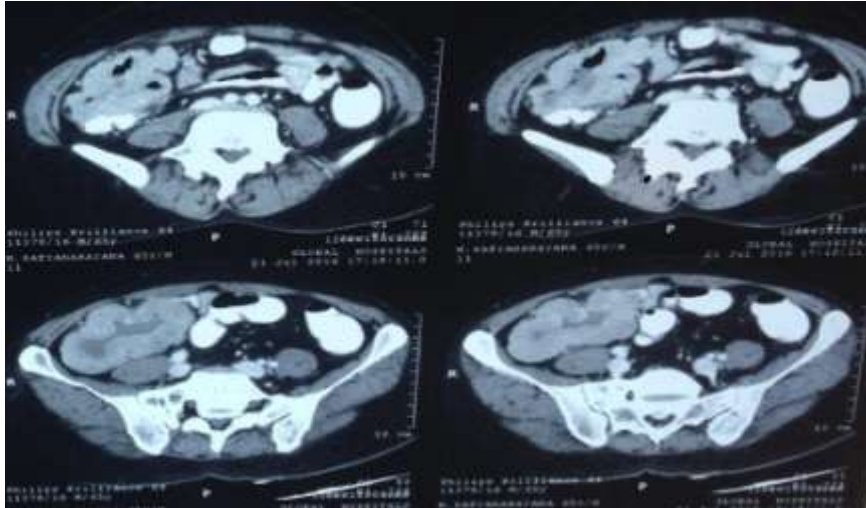
Gastrointestinal stromal tumor (GIST) is the most common(80%) mesenchymal tumor of the alimentary canal. It accounts for less than 1% of all gastrointestinal tumors and about 5% all sarcomas. It represents a wide clinical spectrum of tumors with different clinical presentations, locations, histology and prognosis. GIST can occur throughout the entire gastrointestinal (GI) tract and may have extragastrintestinal involvement as well. The clinical relevance of this tumor was generated by the discovery of its molecular biology and, consequently, of a drug effective in treating the tumor.

### Case Report



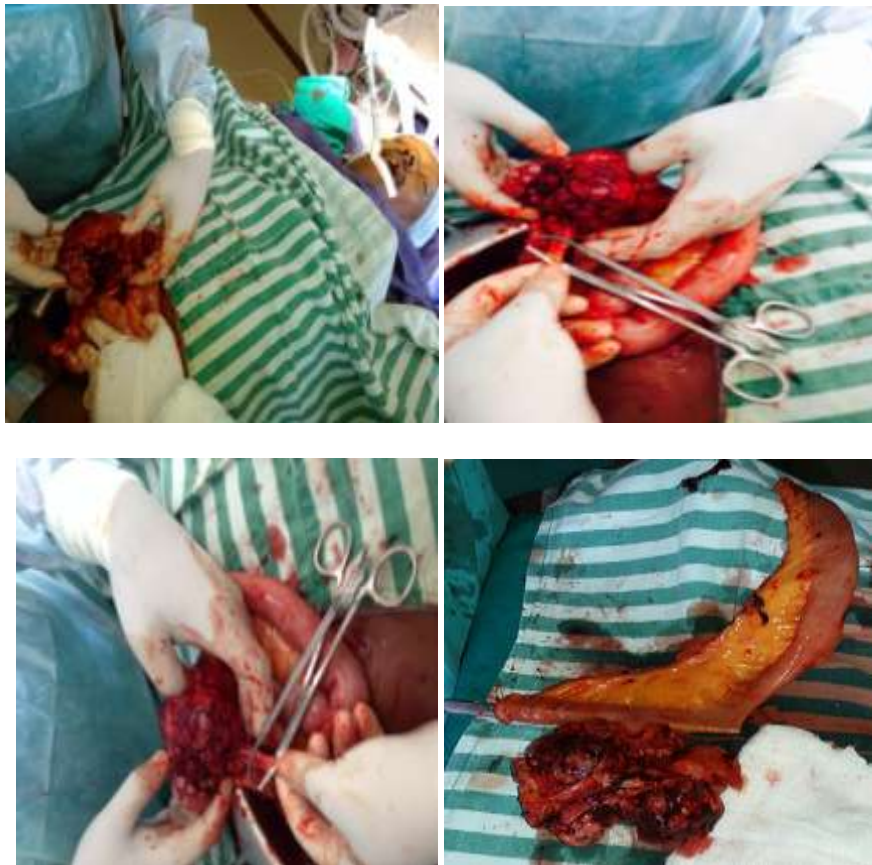
A 45 years old male patient came to the OPD with complaint of pain lower abdomen, vomiting's since 3 days, no h/o fever. On examination about 3\*3 cm irregular shaped mass in Right iliac fossa, tenderness present, with localized guarding. And patient was admitted and routine blood investigations and Ultrasonography was done. Showed elevated total count. USG Report was Appendicular mass. Then we planned for conservative management for appendicular mass by OCHNER'S SHERREN REGIMEN. Patient was responded to OS Regimen and there was symptomatic improvement and progressive decrease in size of mass noticed. And patient was discharged and advised to come after 6 weeks for interval Appendectomy.

After 2 months of discharge, again came with complaint of pain lower abdomen, constipation, loss of weight and loss appetite. On examination there was mass of size 12\*8 cm in RIF, firm in consistency, with restricted mobility, with tenderness. Repeat ultrasonography given as Appendicular mass / Ileocaecocolic's. CECT Abdomen showed – Large lobulated mass S/O Malignancy( GIST), and Focal lesion in liver could be metastasis. Colonoscopy – Mucosal study normal upto terminal ileum and there is extrinsic compression onto caecum. And with this information we planned for Exploratory Laparotomy after other investigation for fitness for anaesthesia.



Cect Abdomen

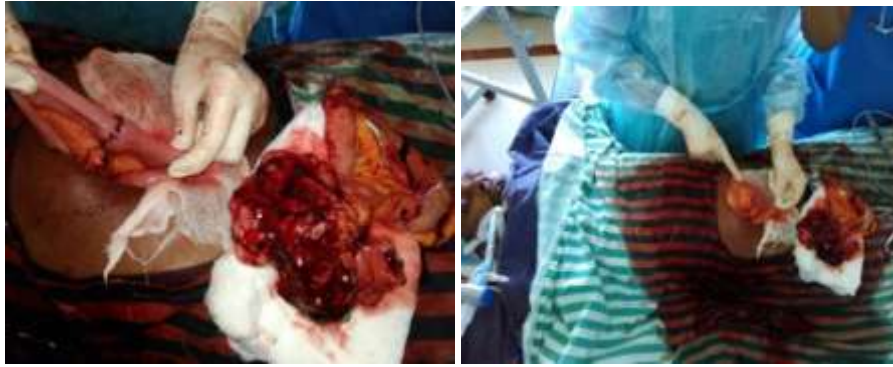Operative findings: A) Nodular mass of size 15cm \* 10 cm arising from serosa of Jejunum with areas of haemorrhage and necrosis and abutting onto Caecum and is adherent to caecocolomesentery , proximal Ileum jejunum and Appendix, occupying entire right iliac fossa. B ) a nodule of size 2\*2 cm noted in caudad's segment of liver. Rest of the abdomen is normal.



Appendectomy

bowel lumen patent – subserosal type

**Procedure:** Segmental resection of Jejunum along with mass and primary JejunoIleal anastomosis and Appendectomy was done and specimen send for HPE. Postoperatively patient recovered well and wound healthy and kept on IMATINIB 400mg per day followed upto 6 months and patient had gained weight and no further complaints.



**Resection and anastomosis**

## **II. Discussion**

Gastrointestinal stromal is rare tumor of GI tract- 0.2 % all GI tumor, but it is the most common non epithelial tumor of the GIT. Stomach is the most common site of all GIST – 60%, Jejunum and Ileum – 30%, duodenum- 5%. It is equal in both sexes and common between 50-70 years of age group. GIST arise of from interstitial cell of Cajal ( pacemaker cell which intercalates between smooth muscle cell and intramural neurons ) . Mutation of tyrosine kinase and platelets derived growth factor alpha ( PDGF alpha ) are the newer pathogenetic theories . GIST is classified as very low risk (2cm ) , low risk ( 2-5cm ) , intermediate risk ( 5-10 cm ) , and high risk ( > 10cm ) based on tumor size and mitotic activity of cells. 95% of GISTs express c-kit – CD 117 mutations- a specific molecular marker. Kit proteins ( CD117, stem cell factor receptor ) is trans membrane tyrosine kinase receptor which is detected by Immunohistochemistry .It distinguishes from true smooth muscle neoplasms. 80% of GIST's are positive for CD 34 –Hematopoietic progenitor cell antigen. Mutations occur in kit ( c-kit ) as exon 11 (70%) or exons 8,9,13, 17. It can occur as mutation in PDGFRA in exons 12,14,qnd 18. Familial GIST 's occur as autosomal dominant with mutations of Germiline gene KIT or PDGFRA. Multiple GIST 's in small bowel , colon, stomach are common. It is associated with urticaria and Hyperpigmentation. It can be spindle shaped ( 70% ) and epithelioid ( 25%), combination.

**Clinical presentation** :Most GIST 's remain silent until reaching a large size. Symptoms vary according to location and size. Symptomatic GIST patients generally present with nonspecificsymptoms including abdominal pain, fatigue, dyspepsia, nausea, anorexia, weight loss, fever, and obstruction. Some patients may present with chronic GI or overt bleeding due to mucosal ulceration or tumor rupture with life threatening intraperitoneal hemorrhage. Some patients with large GIST may have externally palpable mass. Mass is extra luminal as it is of sub mucosal origin, but expands and compress the mucosa. 50% GIST 's can present as metastatic disease to the liver and peritoneum- Ascites. GIST "s almost never metastasis to regional lymph nodes .

**Diagnosis** : The diagnostic evaluation of GIST s is based on imaging technique's, with a special role of endoscopic examination because it is usually accessible when tumors are in the stomach, esophagus, and small and large intestine. In addition , endoscopic ultrasonography ( EUS ) also plays an important role in the diagnostic work –up of GIST and is accurate and efficient in the diagnosis of GIST 's . Imaging's like USG and mainly CECT Abdomen which shows ulceration , calcification, necrosis, caustic areas, spread, metastasis, ascites. Tumor / molecular marker to differentiate it from sarcomas ( immunohistochemistry ) . Endosonography guided biopsy / guided FNAC to get histological confirmation. 18 FDG PET Scan is very useful adjunct to CT but reserved for different / equivocal cases.

**Treatment** : The only potentially curative treatment of GISTs , still, is complete surgical resection if it is a locally resectable or marginally resectable .GIST S rarely metastasize to lymph node and therefore regional lymph node dissection is generally not needed . In addition, organ sparing resection ( segmental resection) is also appropriate oncologically. However , about 40-90 % of surgically treated patients experience disease recurrence . A recent study of 127 patients with localized GIST s who underwent complete resection demonstrated a 5 years recurrence – free survival rate of 63 % . Adjuvant therapy – Imatinibmesylate – specific oral drug that inactivates tyrosine kinase kit and so prevent phosphorylation of the receptor and proliferation of tumor is very much beneficial in advanced cases. Duration of Imatinib is usually one year , dose – 400mg / day. Newer drugs – SUII248 Inhibits tyrosine kinase receptor as well as blocks PDGFRA . ANOTHER NEWER DERIVATIVES – sunitinib, dasatinib.

**Prognostic factors** : Prognosis depends of size of tumor, Tumor site , surgical margins , status of tumor rupture and mitotic activity ( >15 mitoses per 30 high power fields ) and mixed pathology, liver spread KIT exons 9 mutations which is more aggressive than kit exon 11 mutations \_ carries poor prognosis.

### **III. Conclusion**

GIST's have received much attention for many reasons. Appendicular mass is most common differential diagnosis to think in Right iliac fossa mass. If Appendicular mass is not resolved with conservative management ( OSR ) , consider other differential diagnosis. Jejunal tumors / GIST presenting as RIF mass is very **rare as in our case** . Rarely jejunal tumors ( GIST ) MAY ALSO PRESENT AS RIF mass.